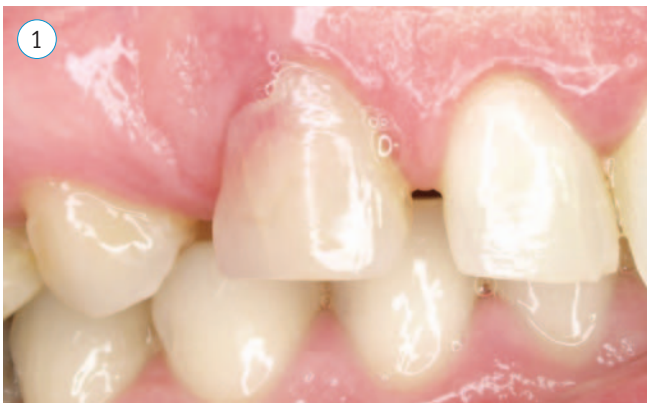

# Immediate Placement, Grafting and Provisional, Non-Occlusal Loading of an Implant in the Maxillary Canine Region: Case Report.

Daniel Capitán-Maraver, DDS, Graduate Professor of Implantology and Prosthetics, and Masters in Dental Sciences Research from the Universidad de Barcelona [University of Barcelona].

## SUMMARY

Tooth extraction followed by immediate implant placement, grafting and delivery of a non-occluding prosthesis in the anterior esthetic zone are now a part of everyday clinical practice. The following case illustrates this technique with a *Trabecular Metal™* Dental Implant (Zimmer Dental Inc., Carlsbad, CA) immediately placed in the maxillary canine location accompanied by guided bone regeneration with *Puros®* Cancellous Particulate Allograft and a free connective tissue graft from the palate.



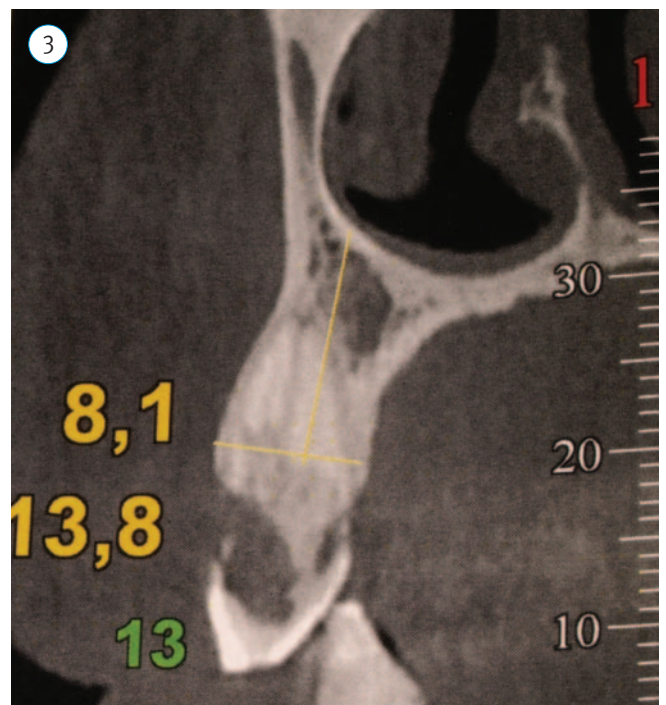
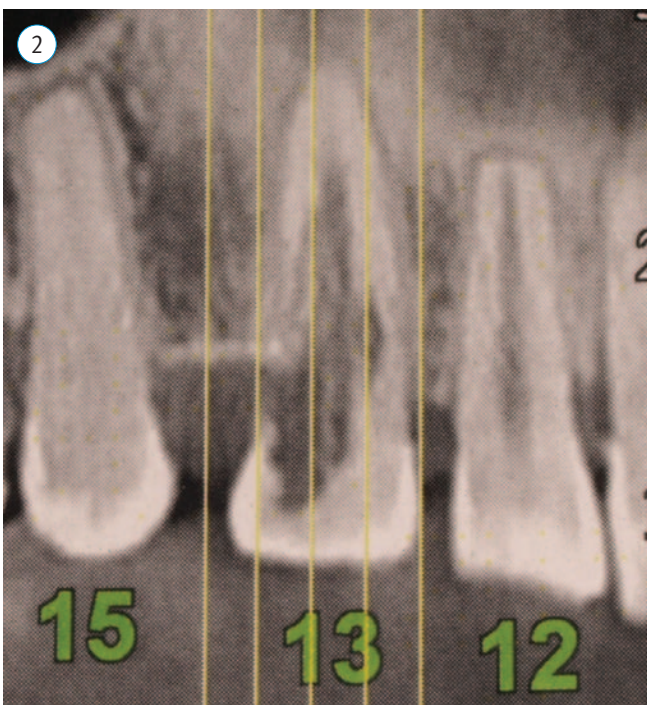
## INTRODUCTION

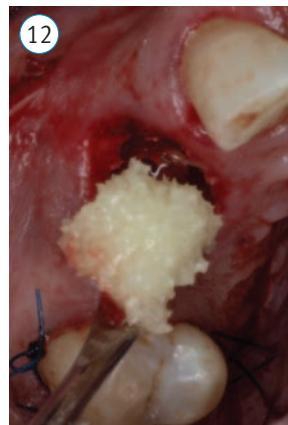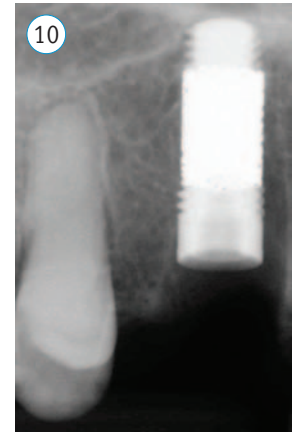
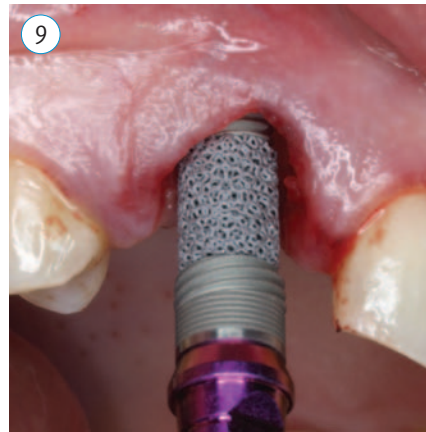

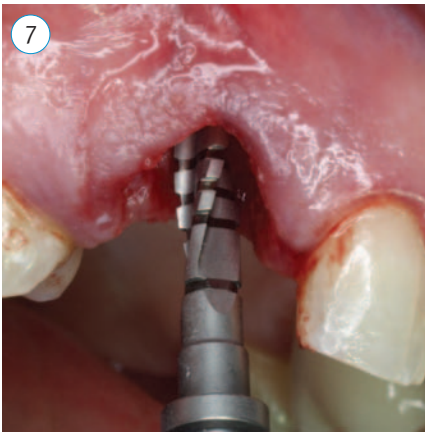
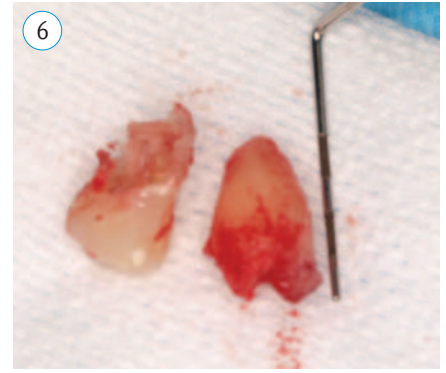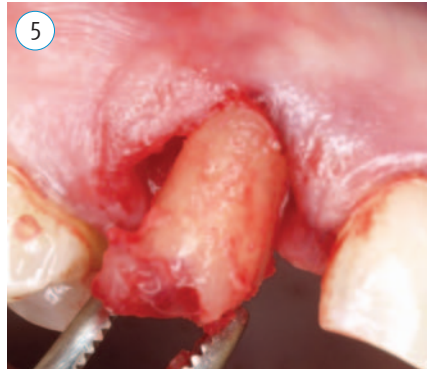
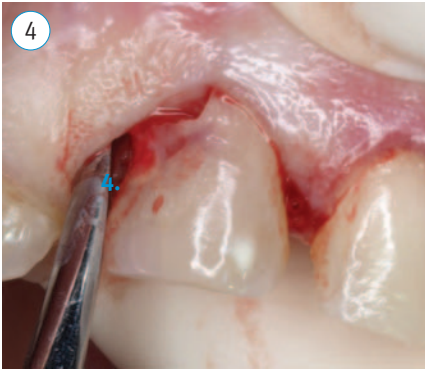
Traditional implantology from the 1980s has now given way to a more modern implantology that focuses on shortening surgical times, limiting costs, and providing immediate esthetics. Numerous studies have reported that long-term (3-7 years) survival rates of dental implants immediately placed in a tooth extraction socket were similar to delayed implantation in healed extraction sites.<sup>1-3</sup>

The esthetic importance that increasingly governs the standards of our society has made the irreversible loss of a tooth in the anterior section something needing to be solved as quickly, conveniently and aesthetically as possible for our patients. The extraction of a tooth in the anterior section, the wait of approximately two months for the placement of an implant and subsequent rehabilitation can have a significant anatomical effect on the area due to the inevitable remodeling of hard and soft tissues,<sup>4-5</sup> as well as a psychological effect on the patient.

## MATERIALS AND METHODS

A 32-year old woman with no relevant disease history or known allergies presented with internal discoloration of





a maxillary right canine, which had developed for over 1 year. During the clinical examination, external resorption was present at the cemento-enamel junction of the canine and reddish discoloration of the crown. Percussion and vitality evaluations were negative. (Figure 1)

Periapical and panoramic radiographs showed external resorption of more than 2/3 of the root. (Figures 2-3)

Two treatments were proposed:

- Extraction of the canine with alveolar preservation and delayed placement of the implant in 3 months.
- Extraction of the canine, immediate implant placement and provisionalization.

After the clinical examination and other tests, the patient opted for the second treatment plan, plus palatal

connective tissue graft and filling of the gap between the alveolus and implant with graft material, per the current recommendations described by Ferrús et al.<sup>6</sup> and Vignoletti et al.<sup>7</sup>

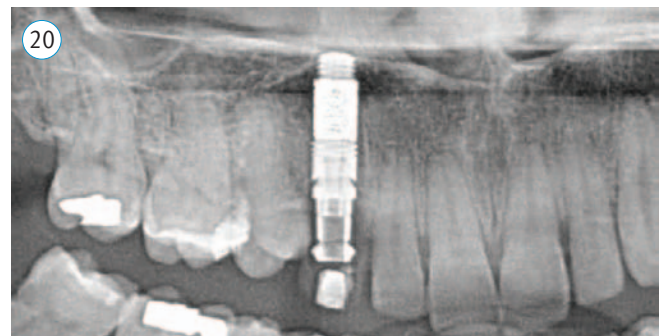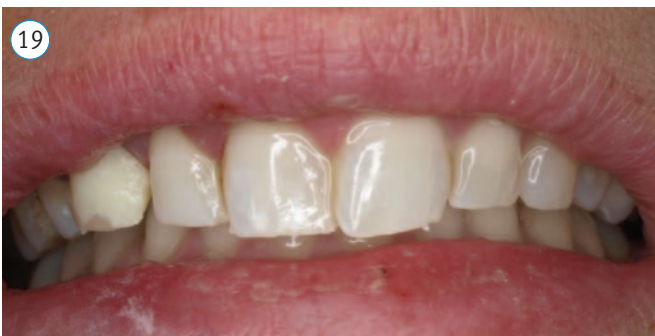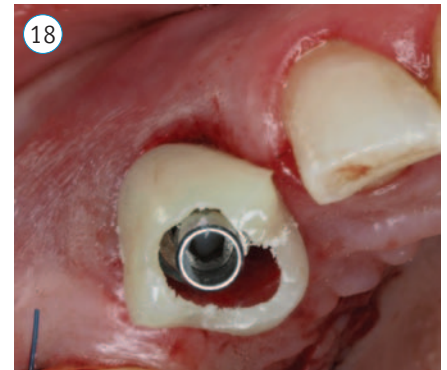
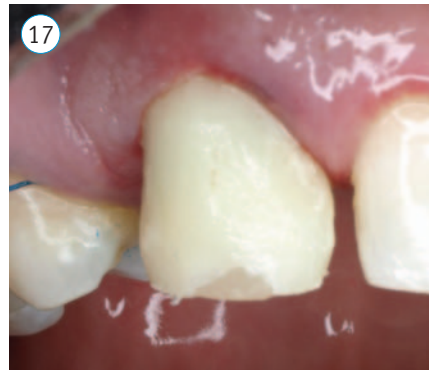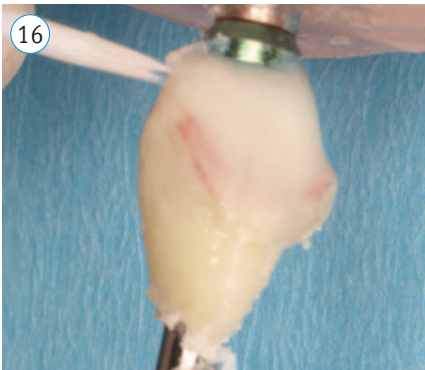
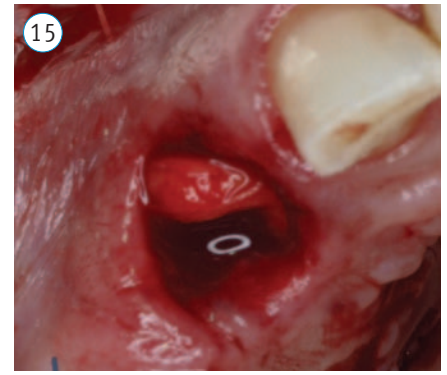
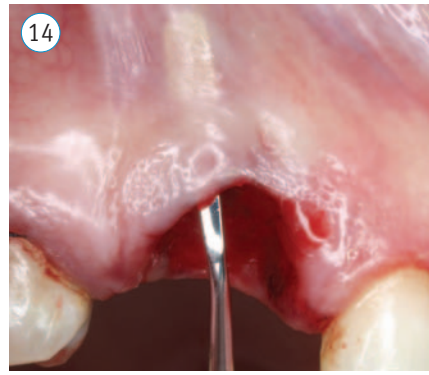
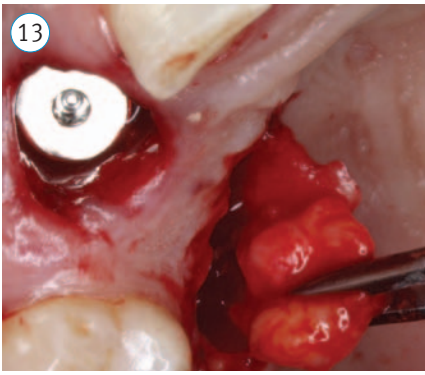
Antibiotic prophylaxis with clomoxyl 750, 1 unit every 8 hours two days before surgery and chlorhexidine mouthwash five days prior at two rinses per day were prescribed.

The surgical procedure is described below:

- Anesthesia via infiltration with 4% articaine containing 1:100 adrenaline in the vestibular and palatine canine areas, and in the palatal donor site for the connective tissue graft.
- Non-traumatic dislocation and avulsion of the canine. (Figures 4-5)
- Curettage of the area, bone integrity assessment of the buccal plate, exploration of the root. (Figure 6)

The implant receptor site was prepared by sequential drilling palatally inside the extraction socket at 1200 rpm. A *Trabecular Metal* Dental Implant (Zimmer Dental Inc.) (4.7 mm x 13 mm) was placed in the osteotomy at 35 Ncm of torque (Figures 7-10)

- Gaps around the top of the implant were filled with small *Puros* Cancellous Particulate Allograft (Zimmer Dental Inc.) via a vestibular approach. (Figures 11-12)

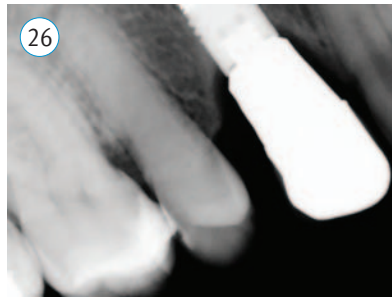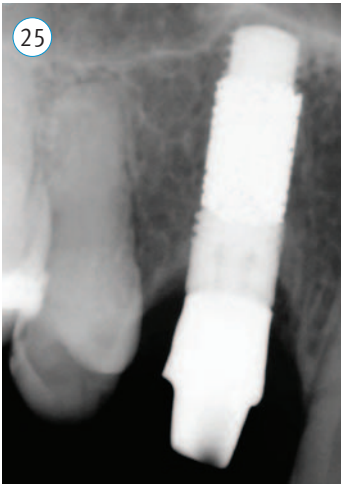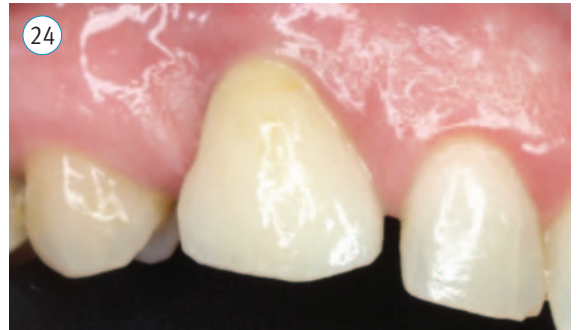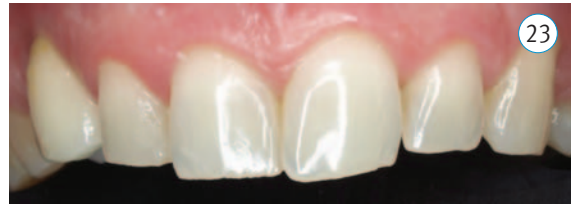
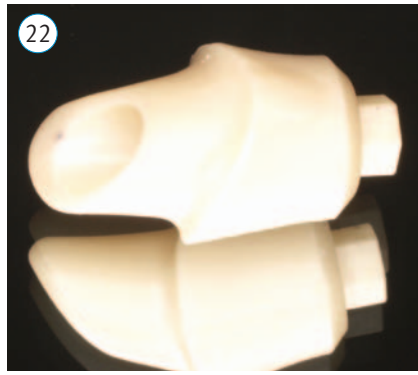


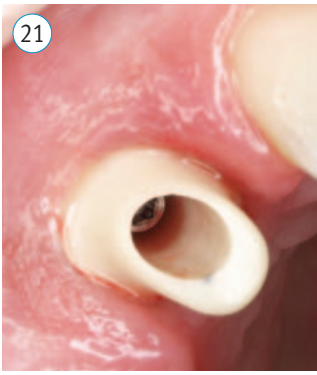- A free connective tissue graft was obtained from the 1st quadrant of the palate to increase soft tissue volume and stability in the implanted area using an envelope technique. (Figures 13-15)
- On the day of surgery, an esthetic provisional restoration was delivered to maintain the natural soft tissue dimensions and prevent its collapse prior to delivery of the final restoration. (Figures 16-20)
- Sutures were removed in 15 days.
- Clinical monitoring and radiographs were taken after one month and four months.
- After four months, the case was definitively restored with a cemented prosthesis using a patient specific zirconia abutment (*Zfx™* CAD/CAM, Zimmer Dental Inc.) and a cemented crown. (Figures 21-25)

- At the 12-month follow-up, the implant was stable and functional with an esthetically pleasing result and minimum bone loss of 0.5 mm from the day of placement. (Figure 26)

## RESULTS

After treatment, optimal mesial and distal marginal bone stability was observed from the time of the surgery until the three-month post-loading check-up, without apparent remodeling. In regard to the soft tissues, from the surgery to placement of the final prosthesis, 2 mm remodeling was observed at the vestibular mucosal level with posterior stability three months from the final placement of the implant. At the 12-month follow-up, the implant was stable and functional with minimal bone loss (0.5 mm) from the day of placement. The final esthetic and functional results fulfilled the patient's expectation that, from the first appointment, she would not spend a single day with a missing tooth or need to wear a removable appliance during periods of bone and mucosa healing.



## DISCUSSION

The use of Zimmer Dental's *Trabecular Metal* Dental Implant to resolve this surgical case demonstrated that it provides primary surgical stability. The interconnected porosity of *Trabecular Metal* Material is designed to enhance secondary stability through a high volume of ingrowth into the pores and onto the struts of the material (osseoincorporation).

## CONCLUSIONS

Today, modern surgical and regenerative techniques with implants immediately placed into prepared extraction\* sockets, predictable gap regeneration with biomaterials and soft tissue grafts, and immediate, esthetic restorations make implant treatment more acceptable to patients. The advantage of this technique in appropriately selected cases is the reduction of the surgical recovery time, and the ability to minimize the remodeling of hard and soft tissues that always occurs after any dental extraction.<sup>8</sup>

**\*Follow instructions for use:** care must taken to evaluate the quality and quantity of the residual bone, especially when it will be immediately placed into extraction sites.

## REFERENCES

- Schulte W., Kleinekenscheidt H., Linder K., Schareyka R. The Tubingen immediate implant in clinical studies. *Dtsch Zahnärztl Zeitschr.* 1978; 33: 348-59.
- Gómez-Román G., Schulte W., d'Hoedt B., Axman-Kremer D. The Frialit-2 implant system: five-year clinical experience in single-tooth and immediately post-extraction applications. *Int J Oral Maxillofac Implant.* 1997;12:299-309.
- Fugazzotto P.A. Simplified technique for immediate implant insertion into extraction sockets: report of technique and preliminary results. *Impl Dent.* 2002;11: 79-82.
- Araujo M.G., Lindhe J. Dimensional ridge alterations following tooth extraction: an experimental study in the dog. *J Clin Periodontol.* 2005;32(2):212-8.
- Cardaropoli G., Araújo M., Lindhe J. 4. Dynamics of bone tissue formation in tooth extraction sites. An experimental study in dogs. *J Clin Periodontol.* 2003 Sep;30(9):809-18.
- Ferrus J., Cecchinato D., Pjetursson E.B., Lang N.P., Sanz M., Lindhe J. 4. Factors influencing ridge alterations following immediate implant placement into extraction sockets. *Clin Oral Implants Res.* 2010 Jan;21(1):22-9. Epub 2009 Nov 13.
- Vignoletti F., Matesanz P., Rodrigo D., Figuero E., Martin C., Sanz M. Surgical protocols for ridge preservation after tooth extraction. A systematic review. *Clin Oral Implants Res.* 2012 Feb;23 Suppl 5:22-38. Review.
- Lang N.P., Pun L., Lau K.Y., Li K.Y., Wong M.C. A systematic review on survival and success rates of implants placed immediately into fresh extraction sockets after at least 1 year. *Clin Oral Implants Res.* 2012 Feb;23 Suppl 5:39-66. Review.